

Persistent SARS-CoV-2 infection with repeated clinical recurrence in a patient with common variable immunodeficiency

Marta Dafne Cabanero-Navalon¹, Víctor García-Bustos^{1,*}, Paula Ruiz-Rodríguez², Inaki Comas^{3,4}, Mireia Coscolla², Lúcia Martínez-Priego⁵, Jose Todolí¹, Pedro Moral Moral¹

¹ Department of Internal Medicine and Infectious Diseases, Hospital Universitari i Politecnic La Fe, Valencia, Spain

² Institute for Integrative Systems Biology (I2SysBio), University of Valencia-CSIC, Valencia, Spain

³ Biomedical Institute of Valencia IBV-CSIC, Valencia, Spain

⁴ CIBER of Epidemiology and Public Health, Madrid, Spain

⁵ Servicio de Secuenciación, Fundación para el Fomento de la Investigación Sanitaria y Biomédica de la Comunidad Valenciana (FISABIO), Valencia, Spain

To the Editor,

A 22-year-old man with common variable immunodeficiency complicated by granulomatouslymphocytic interstitial lung disease previously treated with azathioprine and a 4-weekly course of rituximab 3 years earlier who was receiving subcutaneous immunoglobulin replacement therapy was diagnosed with coronavirus disease 2019 (COVID-19) using an RT-PCR for severe acute respiratory syndrome coronavirus 2 (SARS-CoV-2) of a nasopharyngeal swab specimen after a 4-day history of fever. He quarantined at home but was later admitted to the hospital with COVID-19 bilateral pneumonia and hypoxaemia on day 20. He was treated with ceftriaxone, dexamethasone and an extra dose of subcutaneous immunoglobulin replacement therapy, and was discharged on day 27 with positive RT-PCR assay of a nasopharyngeal swab (Ct value 30.1, Figs. 1b and 2b). The patient did not develop a serological response at any time.

On day 38, he was readmitted for relapsing fever and dyspnoea. A SARS-CoV-2 RT-PCR assay was negative, so he was diagnosed

with nosocomial pneumonia and received treatment with piperacillin-tazobactam for 7 days. However, on day 55, hypoxaemia and new bilateral pulmonary infiltrates developed, requiring hospital admission and supplemental oxygen. A bronchoalveolar lavage specimen on day 57 revealed an RT-PCR Ct value of 27.2 (Fig. 1b). A transbronchial biopsy was performed, detecting tissue SARS-CoV-2 RNA. After treatment with piperacillintazobactam, azithromycin and dexamethasone, he was discharged without the need for supplemental oxygen and with infiltrate resolution.

The last admission for fever, radiological progression and mild hypoxaemia was on day 72, and showed another positive RT-PCR assay of a sputum specimen on day 77. The patient received a 10day course of remdesivir, convalescent plasma therapy, dexamethasone and meropenem, with complete clinical and radiographic resolution. Subsequent RT-PCR assays were negative in both upper and lower respiratory samples. No anti-SARS-CoV-2 monoclonal antibodies were available.

Samples on days 4, 26 and 57 were sequenced given the suspected relapse or re-infection. Phylogenetic analysis confirmed persistent infection after a single infection event with clinical relapse. All three isolates belonged to lineage B.1.416.1 and formed a common clade. They showed seven mutations with respect to the reference sequence, including one non-coding mutation, one synonymous single nucleotide polymorphism (SNP), and five nonsynonymous SNPs in nsp6, nsp12 and spike (Fig. 1b, Table S4). Intra-host dynamics were revealed by 19 SNPs that varied in frequency between sampling times where all but one SNP showed intermediate frequencies in at least one of the samples (Fig.1b). The temporal dynamics observed were not compatible with increased diversity corresponding to higher viral load, as previously described in individuals with secondary humoral immunocompromise [1], because sampling points 2 and 3 showed a higher number of polymorphic sites and higher Ct values (Figs. 1b and 2a). Two of the SNPs in the spike gene arising in the second sampling

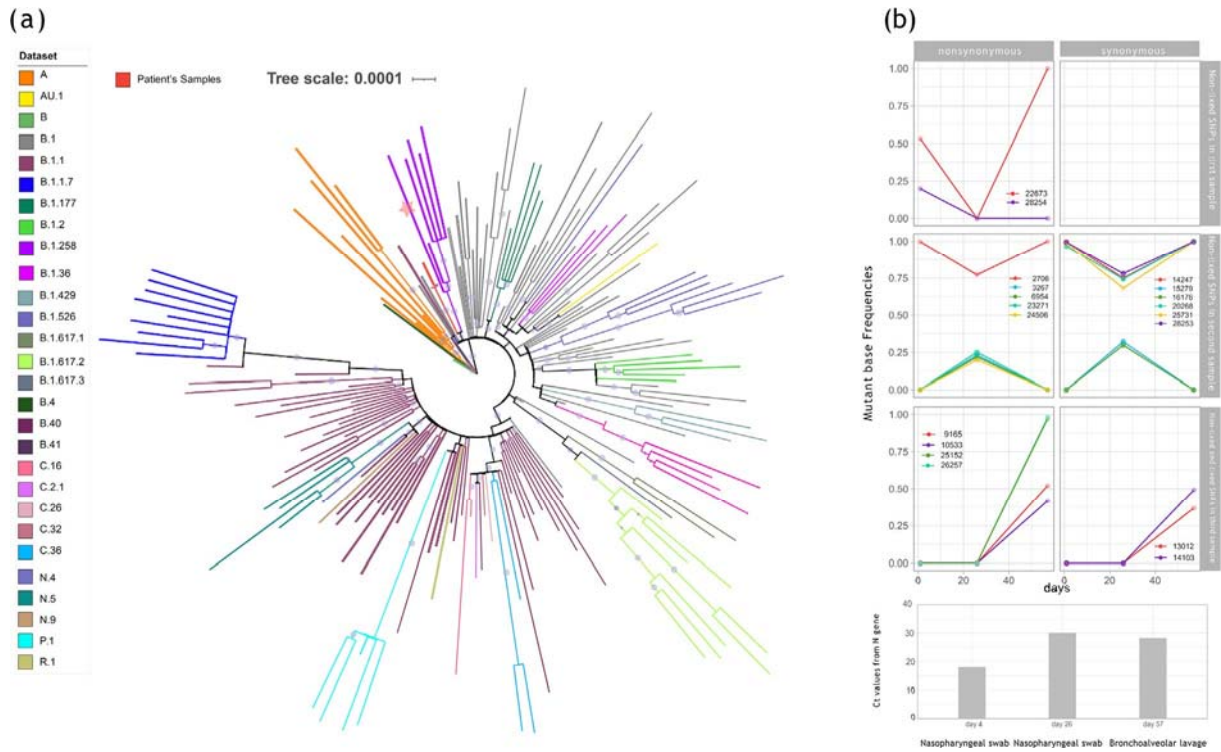


Fig. 1. Whole-genome viral sequencing of subsequent severe acute respiratory syndrome coronavirus 2 (SARS-CoV-2) patient's isolates during hospital admissions. (a) Maximum likelihood phylogeny of 191 SARS-CoV-2 genomes rooted with reference sequence from Wuhan. Bootstrap values ranging from 70 to 100 are represented in nodes as circles whose size is proportional to the value. Branches are coloured by identified PANGO lineages. Branches leading to the three sequences of interest are coloured red and marked with a red star. The scale bar indicates the number of nucleotide substitutions per site. (b) Intra-host variation along three sampling times and its corresponding Cycle threshold (Ct) values detected for N gene. Non-synonymous changes are plotted in panels on the left and synonymous changes on the right. Upper panel shows non-fixed single nucleotide polymorphisms (SNPs) in the first sample, middle panel shows non-fixed SNPs in the second sample, and lower panel shows non-fixed and fixed SNPs in the third sample.

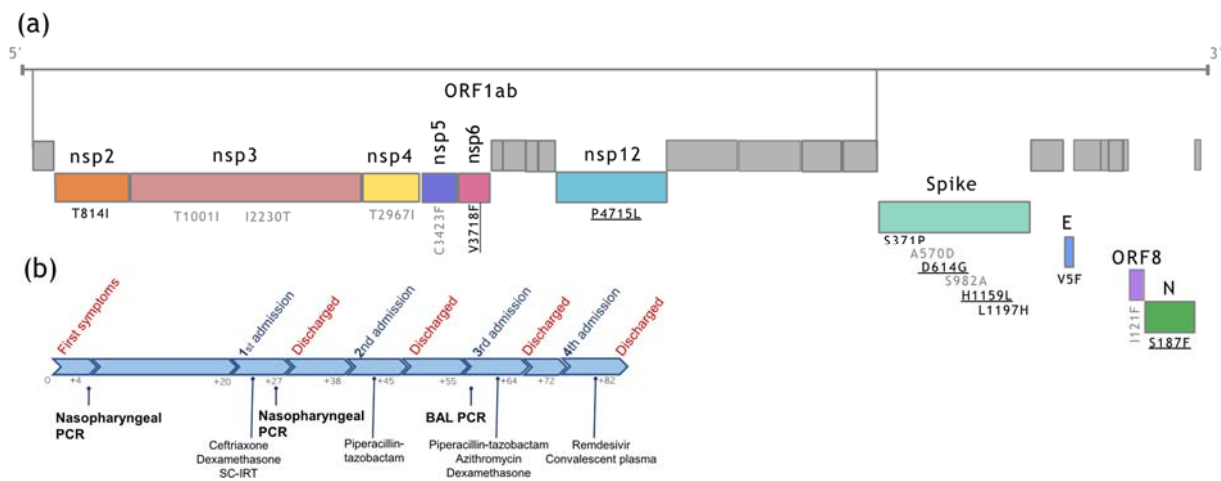


Fig. 2. Amino acid replacements in the sequenced samples and timeline of the severe acute respiratory syndrome coronavirus 2 (SARS-CoV-2) infection course in our patient. (a) Amino acid replacements found in at least one of three analysed samples indicated on a graphical representation of the SARS-CoV-2 genome. Amino acid replacements in black indicate those fixed in at least one of the samples, in grey those that only appeared transitorily but did not get fixed. Underlined amino acid replacements are the ones shared by all three sampling points. (b) Timeline of patient's clinical evolution, hospital admissions, virological studies and treatments. BAL, bronchoalveolar lavage.

time have been also described in the lineage B.1.1.7 (Alpha) but they did not become fixed in the population. The sequence on day 57 had the largest number of fixed changes. Plasma immunoglobulin levels were normal (Fig. S1C), but virus-induced low B-cell and Tcell counts (Table S3) were revealed by flow cytometry analysis.

Interestingly, accelerated viral evolution was observed in this case as previously described in individuals with secondary humoral immunocompromise [1e4], as a result of mutations without recombination evidence seen in other coronaviruses such as HCoV-OC43. This fact may advocate for immunocompromised patients as important contributors in

generating viral genetic diversity and the emergence of new variants, especially after confirming its selective active persistence in the lower respiratory tract with negative nasopharyngeal swab samples, as recently suggested in a report of a patient with X-linked agammaglobulinaemia [5]. Furthermore, the clinical relapses of this patient without detectable SARS-CoV-2 in the upper airways may imply that standard nasopharyngeal swab samples are not adequate in patients with primary immunodeficiencies and, perhaps, also in secondarily immunocompromised patients. Despite plasma RT-PCR not being routinely performed, it should be considered in B-cell-depleted patients, especially after Hueso et al. [5] effectively monitored RNAemia and correlated it with clinical improvement after early convalescent plasma therapy. Additionally, treatment with the combination of remdesivir and hyperimmune plasma was able to finally eradicate this reservoir, as also reported by Palomba et al. [6]. However, the selection pressure after plasma therapy in patients with primary immunodeficiencies with reduced inherent clearance capability could potentially give rise to escape mutations with reduced susceptibility to polyclonal neutralizing antibodies [2]. However, early plasma therapy should be considered in patients unable to elicit a specific humoral response against SARSCoV-2 as previously demonstrated in B-cell-depleted patients with protracted COVID-19 [5]. Further information is needed on viral intrahost dynamics in immunocompromised patients with prolonged viral shedding for clinical

management and public health purposes, as well as for understanding the appearance of new variants of concern.

This report highlights the potential capability of SARS-CoV-2 for causing prolonged relapsing infections in patients with treated primary immunodeficiency and its associated accelerated within-host genomic evolution, as well as the role of the combination of remdesivir and convalescent plasma therapy in eliminating its reservoir in the lower respiratory tract [3e5].

Transparency declaration

The authors report no conflicts of interest for the present work. Funding: This work was co-financed by the European Union through the Operational Programme of the European Regional Development Fund of Valencia Region (Spain) 2014e2020.

Author contributions

MDCN, VGB and PMM conceived the idea, searched the bibliographic materials, reviewed the existing literature and wrote the article. PRR, IC and MC developed the figures, aided in the search of the bibliographic materials and

contributed to the writing of the article. LMP sequenced the samples. JTP reviewed the literature and contributed to the writing of the article. VGB and PMM were responsible for the care of the patient during hospital admissions. PMM supervised the work. All authors provided critical feedback and helped to shape the final version of the manuscript.

Appendix A. Supplementary data

Supplementary data to this article can be found online at <https://doi.org/10.1016/j.cmi.2021.10.021>.

References

- [1] Choudhary MC, Crain CR, Qiu X, Hanage W, Li JZ. SARS-CoV-2 sequence characteristics of COVID-19 persistence and reinfection. *Clin Infect Dis* 2021: ciab380.
- [2] Kemp SA, Collier DA, Datir RP, Ferreira IATM, Gayed S, Jahun A, et al. SARS-CoV2 evolution during treatment of chronic infection. *Nature* 2021;592:277e82.
- [3] Sepulcri C, Dentone C, Mikulska M, Bruzzone B, Lai A, Fenoglio D, et al. The longest persistence of viable SARS-CoV-2 with recurrence of viremia and relapsing symptomatic COVID-19 in an immunocompromised patient: a case study. *Open Forum Infect Dis* 2021;8:ofab217.
- [4] Choi B, Choudhary MC, Regan J, Sparks JA, Padera RF, Qiu X, et al. Persistence and evolution of SARS-CoV-2 in an immunocompromised host. *N Engl J Med* 2020;383:2291e3.
- [5] Hueso T, Poudroux C, Pere H, Beaumont AL, Raillon LA, Ader F, et al. Convalescent plasma therapy for B-cell-depleted patients with protracted COVID-19. *Blood* 2020;136:2290e5.
- [6] Palomba E, Carrabba M, Zuglian G, Alagna L, Saltini P, Fortina V, et al. Treatment of SARS-CoV-2 relapse with remdesivir and neutralizing antibodies cocktail in a patient

with X-linked agammaglobulinemia. *Int J Infect Dis*
2021;S1201e9712:
338e40.