

Camino Gestal, Santiago Pascual, and Sarah Culloty

### Abstract

Neoplasia are growth disturbances characterized by excessive, abnormal proliferation of cells, independent of normal-regulating mechanisms of the animal and persisting after termination of the stimulus that initiated growth. Over last years there has been an increase in research into tumors of invertebrates. In cephalopods, reports on the incidence of the tumors or neoplasia are scarce. They have been described as hard compact and homogeneous nodules of connective tissue located in the mantle or at the base of suckers. The aetiological origin of tumors observed in cephalopods is unknown, but it could be related to aquarium maintenance. Other injurious agents, including infectious (virus, bacteria, or parasites) and xenobiotics, may also have produced the lesions. In occasions inflammatory processes have been associated with tumors with severe oedema associated. Inflammation is part of the biological response to body tissues to harmful stimuli such as pathogens, damaged cells or effect of xenobiotics. The inflammatory focus is characterized by exudation with interstitial fluid changes and hemocytic migration. Some inflammatory lesions include fibrosis and necrotic cells in the affected area, with loss of histological features and even organ architecture. All these changes have been observed in cephalopods in inflammatory reactions originated by infection with different pathogens. The chapter covers a selection of the reported cases of disorders related to neoplasia and inflammation.

### Keywords

Neoplasia • Tumors • Inflammation • Haemocytic infiltration • Aedema

C. Gestal (✉)

Aquatic Molecular Pathobiology Group, Institute of Marine Research, Spanish National Research Council (CSIC), 36208 Vigo, Pontevedra, Spain  
e-mail: [cgestal@iim.csic.es](mailto:cgestal@iim.csic.es)

S. Pascual

Ecology and Biodiversity Department, Institute of Marine Research, Spanish National Research Council (CSIC), 36208 Vigo, Pontevedra, Spain  
e-mail: [spascual@iim.csic.es](mailto:spascual@iim.csic.es)

S. Culloty

Aquaculture & Fisheries Development Center, School of Biological, Earth and Environmental Sciences, University College Cork, The Cooperage, Distillery Fields, North Mall, Cork, Ireland  
e-mail: [s.culloty@ucc.ie](mailto:s.culloty@ucc.ie)

## 15.1 Introduction

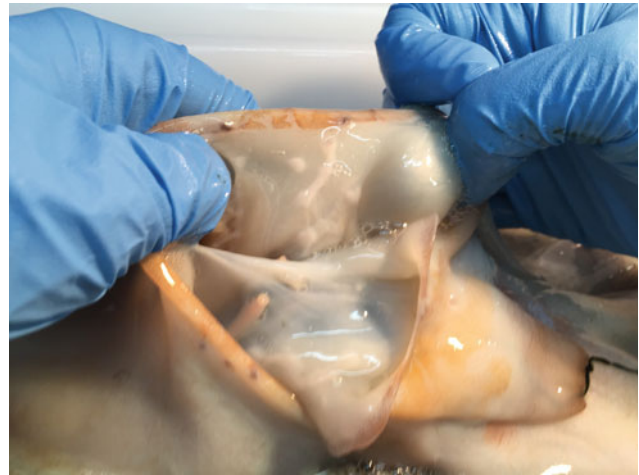Neoplasia are growth disturbances characterized by excessive, abnormal proliferation of cells, independent of normal-regulating mechanisms of the animal and persisting after termination of the stimulus that initiated growth (Sparks 1985). Similarly, tumors are ectopic masses of tissue formed by due to an abnormal cell proliferation. Over last years there has been an increase in research into tumors of invertebrates, since previously it was thought that tumors only occurred in vertebrates and invertebrates were not susceptible to developing neoplasia (Engel 1930). Nowadays the research in the area has increased and increasing number of tumors has been

detected in these organisms. Thus, histological and molecular research has provided a better understanding of the nature of these abnormal growths (Tascedda and Ottaviani 2014). In marine invertebrates, different types of tumors have been described, namely those emerged spontaneously, those due to hereditary phenomena, and those due to a wide range of environmental factors. Among those induced by environmental factors, different injurious agents including chemical toxins, physical stress, biological infections and potential carcinogenic substances, may produce that lesions (Hanlon and Forsythe 1990a). In molluscs, tumors, tumor-like growths or neoplasia have been described in gastropods, bivalves, and in some cases in cephalopods. In bivalves, sarcomas of hematopoietic origin such as disseminated neoplasia, or gonad neoplasia have been identified as causative of important mortalities (Carballal et al. 2015). Very few reports have been published in cephalopods.

Other disorder commonly observed in cephalopods is inflammation. It is part of the biological response to body tissues to harmful stimuli such as pathogens, damaged cells, or effect of xenobiotics. Inflammation is a protective response with a function of eliminates the initial cause of the cell injury, clear out necrotic cells and tissues damaged and initiate tissue repair. The description of the tissue modifications occurred in relation to infectious or non-infectious agents by histopathological analysis is essential for an accurate diagnosis of the disease.

## 15.2 Neoplasia and Tumors

In cephalopods, the incidence of the tumors or neoplasia is extremely low. In 1951 Jullien and Jullien (1951) reported cuttlefish with hard compact and homogeneous whitish nodules of connective tissue with loss of normal stratified appearance and highly vascularized at the periphery. In some cases, haemocytic infiltration is observed between the connective tissue and muscular fibers (Wauttier and Wautier 1955). Similar nodules were also observed in *Octopus vulgaris* (Figs. 15.1 and 15.2). Nigmatullin provided morphological data on tumors observed in *O. vulgaris* off the northwest coast of Africa with a prevalence of 1.6% of caught octopus. Pascual et al. (2006) described lesions characterized by consistent swelling of smooth surface nodules located at the sucker's base and mantle of *Octopus hubbsorum* (Figs. 15.3 and 15.4). At histological level, the lesions appear as mass proliferations of dense fibrous tissue between the dermis and muscle layers (Fig. 15.4a–c). Muscular tissue surrounding the lesions was degenerated and necrotic foci were observed (Figs. 15.2 and 15.4). The aetiological origin of tumors observed in cephalopods is



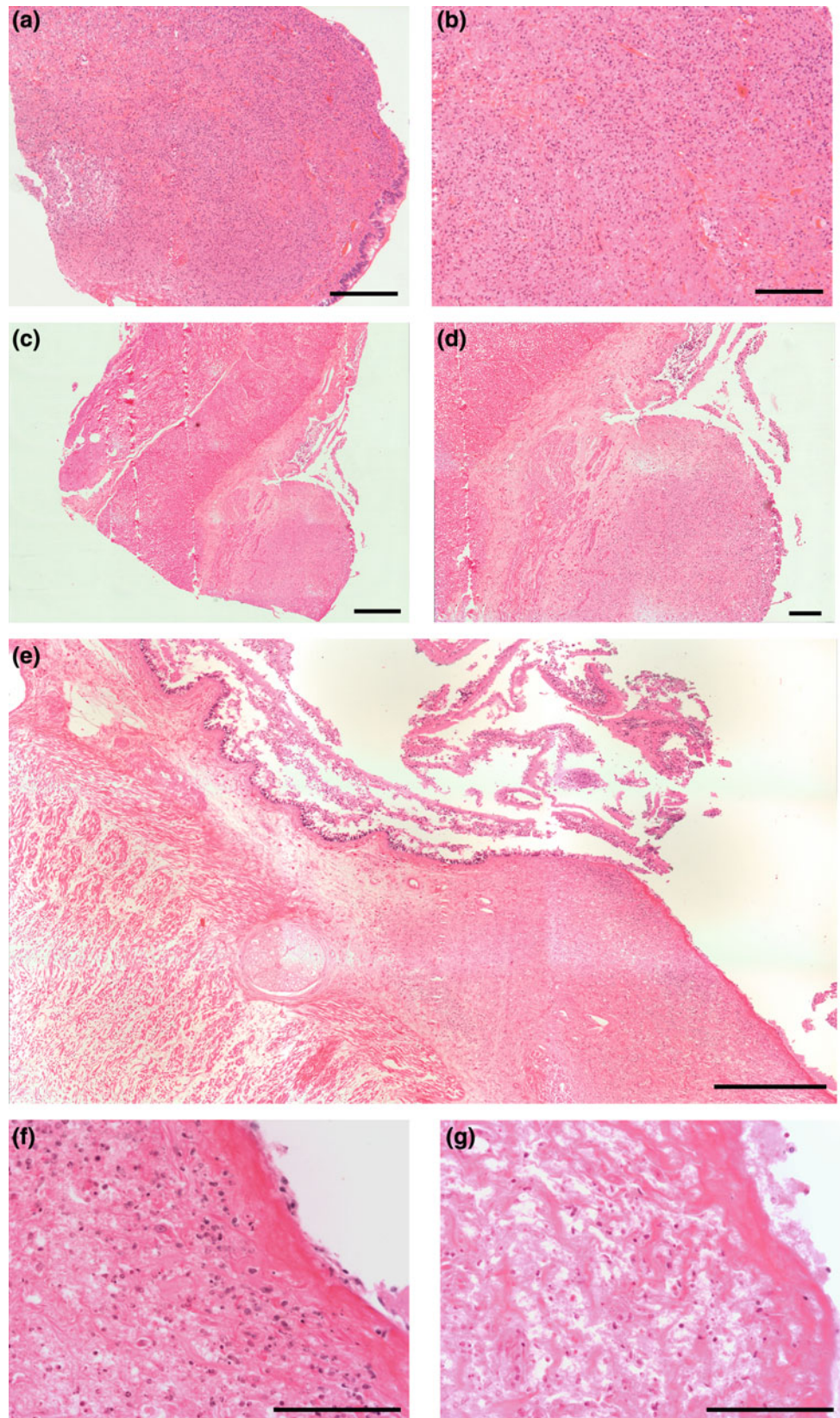
**Fig. 15.1** Macroscopic aspect of nodules located at internal mantle side of *Octopus vulgaris*

unknown, especially in those observed in wild individual. However, different authors suggest that it could be the result of traumatic episodes related to aquarium maintenance (Hanlon and Forsythe 1990b). Other injurious agents, including infectious (virus, bacteria or parasites) and xenobiotics, may also have produced the lesions (Hanlon and Forsythe 1990a).

## 15.3 Inflammation

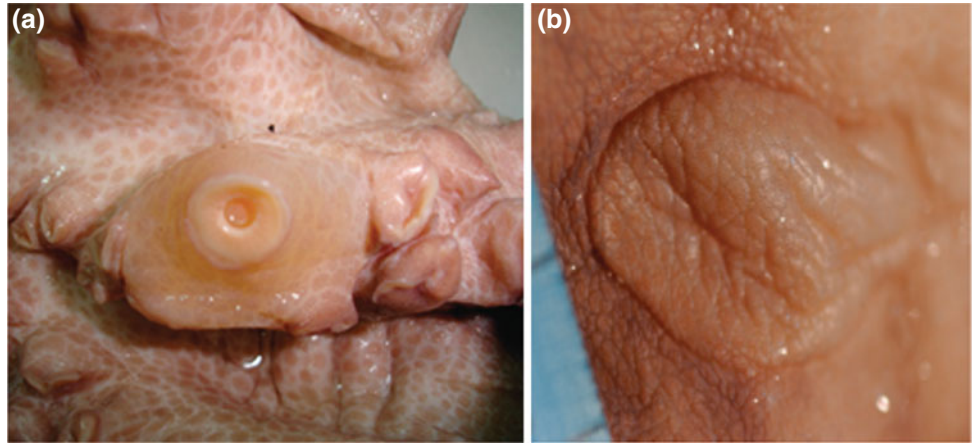
Histologically haemocytic infiltration with eosinophilic staining is observed in the intercellular space of a tissue with inflammation. The inflammatory focus is characterized by exudation with interstitial fluid changes and hemocytic migration. Some inflammatory lesions include fibrosis and necrotic cells in the affected area, with loss of histological features and even organ architecture. All this changes have been observed in cephalopods in inflammatory reactions originated by bacteria, parasites such as the coccidian *Aggregata* or metazoans such as *Anisakis* infections (Fig. 15.5). In occasions, inflammatory processes have been associated with tumors with severe oedema associated. Hanlon and Forsythe (1990a) described the presence of severe edema of the mantle and arms of *O. joubini* and *O. maya*, where epidermis and dermis are separated from the underlying muscle layers, or even the entire dermis of the mantle was separated from the muscle layers by a watery, almost gelatinous, layer of fluid. This condition was always fatal within 48 h. Similar lesions associated to inflammation process have been observed in *Octopus vulgaris* maintained for long period in aquarium installations also with fatal result within 48–72 h (pers. obs.) (Fig. 15.6).

**Fig. 15.2** Histological sections of nodules in *O. vulgaris* (a–g). a–e Detail of mass proliferations of dense fibrous tissue between the dermis and muscle layers. f–g Detail of necrotic foci also observed in a and b. Scale bars a, d, 200  $\mu$ m; b, f, g, 100  $\mu$ m; c, e, 500  $\mu$ m

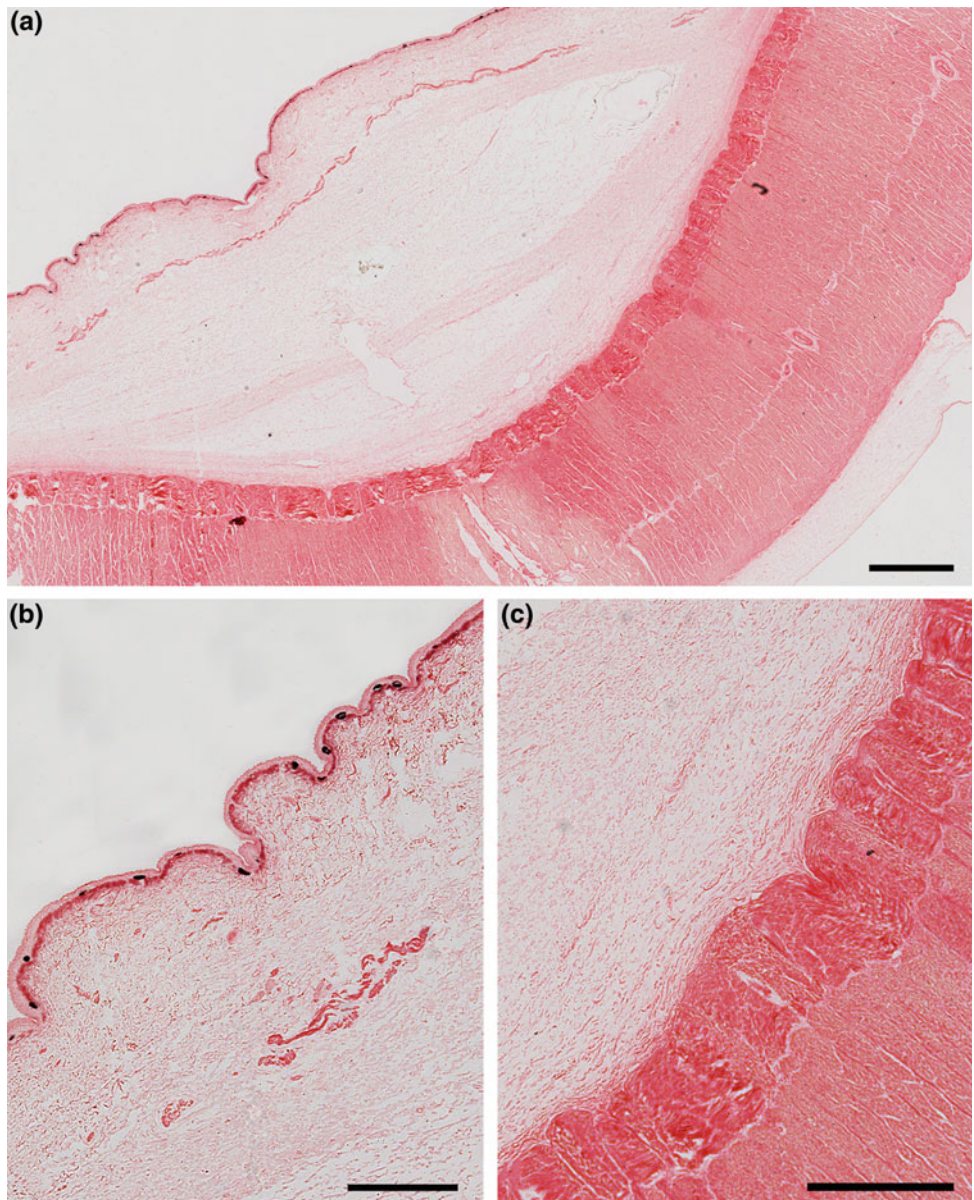


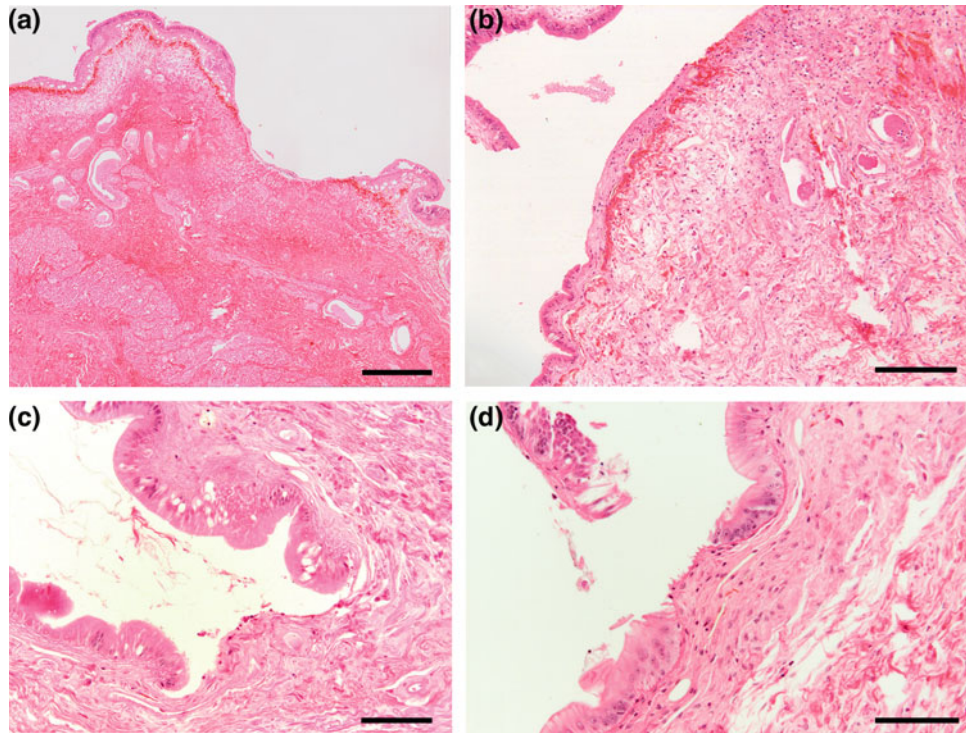


**Fig. 15.3** Macroscopic aspect of nodules located at the sucker's base (a) and mantle (b) of *Octopus hubbsorum*



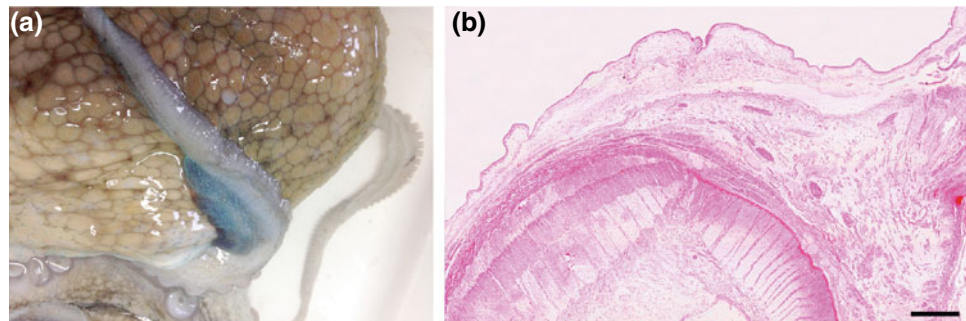
**Fig. 15.4** Histological sections of nodules of *O. hubbsorum*. (a–c) Mass proliferations of dense fibrous tissue between the dermis and muscle layers. Scale bars a, 1 mm; b, c, 500  $\mu$ m





**Fig. 15.5** Inflammatory focus in the mantle of *O. vulgaris* showing exudation with interstitial fluid and hemocytic migration (a–b). Fibrosis and necrotic cells is observed in the affected area (b), with

loss of histological features (epithelium) (c–d) and even organ architecture (a). Scale bars a, 500  $\mu$ m; b, 200  $\mu$ m; c, d, 100  $\mu$ m



**Fig. 15.6** Aedema in the arm of *O. vulgaris* maintained for long period in aquarium installations (a–b). a Macroscopic aspect of aedema focus at arm level characterized by exudation with interstitial fluid accumulation and hemocytic migration. b Histological detail

showing the epidermis and dermis separated from the underlying muscle layers, by a watery, almost gelatinous, layer of fluid close to the sucker. Scale bar b, 1 mm

## 15.4 Concluding Remarks

While the study and identification of neoplasia has been increased in invertebrates and specifically in molluscs in the last years, the incidence of tumors in cephalopods is extremely low. Similarly occurs with histopathological descriptions of biological response or reactive processes of body tissues to

harmful stimuli such as inflammatory reactions. The causes and effects of these disorders are not well studied. However, it is known that at least some of them could be the result of traumatic episodes, both in the wild or related to aquarium maintenance. Therefore, in the context of animal welfare, further research is needed in order to identify and to analyze the progress of those processes to avoid fatal results and to provide the best welfare conditions to the animals in captivity.



## References

- Carballal MJ, Barber BJ, Iglesias D, Villalba A (2015) Neoplastic diseases of marine bivalves. *J Invert Pathol* 131:83–106
- Engel CS (1930) Warum erkranken wirbellose tiere nicht an krebs? *Ztschr F Krebsforsch* 32:531–543
- Hanlon RT, Forsythe JW (1990a) Diseases of Mollusca: Cephalopoda. Structural abnormalities and neoplasia. In: Kinne O (ed) Diseases of marine animals, vol III. Biologische Anstalt Helgoland, Hamburg, pp 47–227
- Hanlon RT, Forsythe JW (1990b) Diseases of Mollusca: Cephalopoda. Diseases caused by protistans and metazoans. In: Kinne O (ed) Diseases of marine animals, vol III. Biologische Anstalt Helgoland, Hamburg, pp 47–227
- Jullien A, Jullien AP (1951) Sur un type de tumeur non provoquée expérimentalement et observée chez la Seiche. *Acad Sci Paris* 210:608–610
- Pascual S, Rocha A, Guerra A (2006) Gross lesions in the Hubb octopus *Octopus hubbsorum*. *Mar Biol Res* 2:420–423
- Sparks AK (1985) Synopsis of invertebrate pathology exclusive of insects. Elsevier, Amsterdam
- Tascedda F, Ottaviani E (2014) Tumors in invertebrates. *Int Sci J* 11:197–203
- Wauttier V, Wautier J (1955) Le cancer et les invertébrés, 1ère partie: réactions tumorales naturelles. *Bull Mens Soc linnéde Lyon* 3:76–96

**Open Access** This chapter is licensed under the terms of the Creative Commons Attribution 4.0 International License (<http://creativecommons.org/licenses/by/4.0/>), which permits use, sharing, adaptation, distribution and reproduction in any medium or format, as long as you give appropriate credit to the original author(s) and the source, provide a link to the Creative Commons licence and indicate if changes were made.

The images or other third party material in this chapter are included in the chapter's Creative Commons licence, unless indicated otherwise in a credit line to the material. If material is not included in the chapter's Creative Commons licence and your intended use is not permitted by statutory regulation or exceeds the permitted use, you will need to obtain permission directly from the copyright holder.

